

2016MAMMO

1 Which of the following is NOT correct description of CC(craniocaudal-View)?

- a) Patient need to stand directly in front of mammography unit
- b) Complementary examination for MLO(mediolateral view).
- c) A blind spot is upper part of breast.
- d) If it includes interior of breast, you don't have to include exterior of breast.

2 Which of the following is the correct description of MLO(mediolateral view)?

- a) Angle of C-arm is always 65°.
- b) You can take breast widest.
- c) A blind spot is exterior part of breast.
- d) Moving compression plate from exterior to interior.

3 Which of the following is the correct description about extra examination for lesion in interior - upper part?

- a) SIO(Superolateral to inferomedial oblique)
- b) AT(Axillary tail)
- c) TAN(Tangential)
- d) CV(Cleavage)

4 Which of the following is the correct reason for extra examination of XCC(eXaggerated Cranio Caudal view)?

- a) When there is lesion in interior - upper part, it is adapted.
- b) Using examination platform for enlargement radiography.
- c) Rotation patient toward mammography unit.
- d) It is standard examination.

5 Which of the following is the correct combine for explain of examination?

- a) XCC(Exaggerated craniocaudal) — exterior breast
- b) LM(Lateromedial) — interior breast
- c) RL(Rolled lateral) — interior breast
- d) FB(From below) — upper breast

6 Which of the following is NOT correct description of how to take mammography?

- a) Taking a enlargement radiography because there is aggregation of calcifications.
- b) Taking XCC(eXaggerated Cranio Caudal view) instead of CC(craniocaudal-View) because there is a lesion at outside.
- c) Angle of receiving material is set parallel to outermost of greater pectoral muscle at MLO(mediolateral view).
- d) Instruct to hold on the arm rail so that it will not ove.

7 Which of the following is NOT correct description of how to take CC(craniocaudal view)?

- a) Standing to situate a target breast in the central region of receiving material
- b) Height of receiving material is equivalent to inframammary fold.
- c) Bend oneself backward to include the lower part of a breast in the field of view.
- d) Bend one's arms to slacken a pectoral muscle.

8 Which of the following is NOT correct standard in MLO(mediolateral oblique view)?

- a) symmetry of both breasts
- b) Nipple is shown at profile.
- c) try not to include abdominal organs
- d) try not to include wrinkles

9 Which of the following is NOT correct of acceptance standard in CC(craniocaudal view)?

- a) symmetry of both breasts
- b) External mammary tissue is always described and internal one is described as possible as.
- c) Nipple is shown at profile.
- d) try not to include wrinkles

10 Which of the following is NOT correct evaluation item about positioning?

- a) symmetry of left and right
- b) sidedness of nipple
- c) position of arms
- d) lower part of breast

11 Which of the following is the correct numerical value of pressure in compression?

- a) 1.2~1.4N
- b) 12~14N
- c) 120~140N
- d) 160~200N

12 Which of the following is NOT correct MLO(Medio Lateral Oblique view) angle for a person who is short with tiny breasts?

- a) 50°
- b) 55°
- c) 60°
- d) 70°

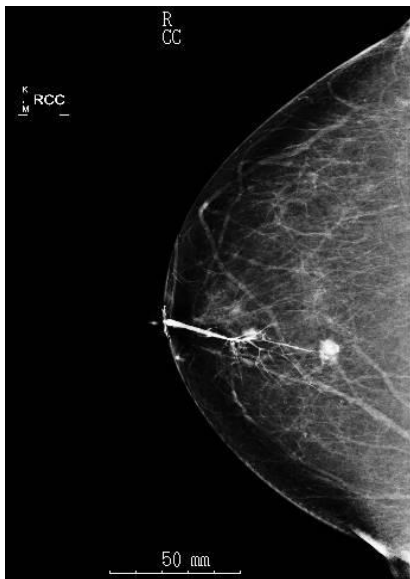13 Which of the following is NOT correct for galactography?

- a) A target is a person who get secretion defect.

- b) To confirm the position of papilloma.
- c) It is important to inject the contrast medium rapidly.
- d) To take biplane radiography.

14 Which of the following image is the correct examination?

- a) magnification radiography
- b) spot-film radiography
- c) tangent radiography
- d) galactography



15 Which of the following is NOT correct description about spot-film radiography?

- a) It is not accepted to a lesion that isn't palpable from outside of body.
- b) Magnification spot-film radiography is the best examination for describing calcification and margin.
- c) It improves sharpness and contrast.

d) A spot-film radiography can describe more clearly than standard examination.

16 Which of the following is NOT correct description about magnification radiography?

a) It is useful to grasp the shape of calcification

b) A grid is unnecessary.

c) It gets better sharpness than closely examination.

d) It needs to choose a small focus.

17 Which of the following is the correct description of mammography grid?

a) Using parallel grid.

b) Using fixing grid.

c) A lot of grid have 12:1 ratio of grid.

d) Intermediate of grid is fober.

18 Which of the following is NOT correct description about effect of compression in mammography?

a) decreasing adsorbed radiation dose of breast

b) decreasing motion artifact

c) decreasing contrast

d) uniformity of density of breast

19 Which of the following is NOT correct description about interpretation on a monitor?

a) Light does not enter a monitor screen directly.

b) A ceiling lamp is indirectly better.

c) Choose thin curtain that gets natural light.

d) Don't stand behind a person interpreting.

Which of the following is NOT correct description about monitor for
20 mammography?

- a) Using the monitor having same brightness to other medical monitors.
- b) You can enlarge as necessary.
- c) You can show images both sides breast images symmetrically.
- d) Using high resolution monitor.

Which of the following is the appropriate brightness value of viewing screen for
21 mammography films?

- a) 3.5 cd/m^2
- b) 35 cd/m^2
- c) 350 cd/m^2
- d) 3500 cd/m^2

When you interpretate mammography films, which of the following is the
22 appropriate the interior illuminance?

- a) 5 lx
- b) 50lx
- c) 500lx
- d) 5000lx

23 Which of the following is NOT correct description about explain of graininess?

- a) Inferior graininess have effect to recognize minute calcification.
- b) Graininess is inferior on a supersensitive film.
- c) easy to evaluate on adipose resion.
- d) Shortage of radiation dose is causing inferior graininess.

24 Which of the following is NOT correct description about sharpness?

- a) Sharpness is the index of clear description of outline and fine line.
- b) evaluate by edge of ligament and calcification.
- c) Body motion causes inferior sharpness.
- d) Strong compression is causing inferior sharpness.

25 Which of the following is NOT correct description about artifact?

- a) Trash and fingerprint are causing mistake.
- b) Hair and shoulder are causing shadow.
- c) Artifact frequency at digital system is higher than film system.
- d) Cleaning monitor screen and viewer are getting prevention some artifact.

26 Which of the following is NOT correct item about daily inspection of mammography?

- a) field lamp
- b) movement of compression plate
- c) cleaning of monitor screen
- d) display accuracy of X-ray tube voltage

27 Why should be the chest wall located by Cathode of X-ray tube in Mammography?

- a) Anode Heel Effect
- b) Line Focus Principle
- c) Filament Heating Unit
- d) Anode Target Material

28 What is the best factor to limit scatter ray? (過去問24)

- a) Target material
- b) kVp
- c) Compression
- d) Filtration

29 Choose the option which is not appropriate as target/filter combination.

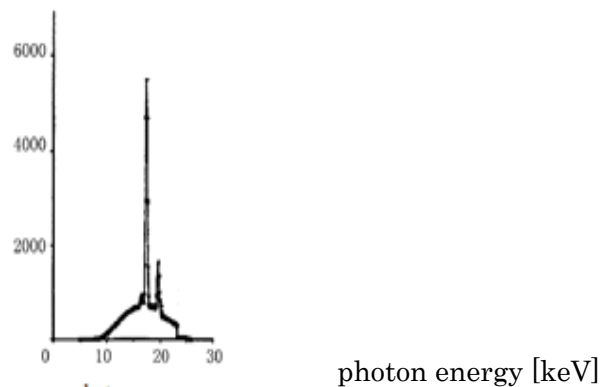
- a) Mo/Mo
- b) Rh/Rh
- c) W/Rh
- d) Rh/Mo

30 Choose the option which is not appropriate as filter.

- a) Mo
- b) Rh
- c) W
- d) Ag

31 Figure 1 shows the energy spectrum. Choose the correct option.

- a) It is the spectrum passed through the breast.
- b) It is the spectrum for rhodium(Rh) target.
- c) It is the spectrum for molybdenum filtered.
- d) It is the spectrum for rodium filtered.



- 32 Choose the incorrect option about molybdenum target.
- a) It has K-characteristic X-ray peaks.
 - b) It has K-absorption edge at 20keV.
 - c) The bremsstrahlung is used mainly.
 - d) K-characteristic peaks is lower than that of rodium.
- 33 Choose the option which is most affected by focal spot size.
- a) sharpness
 - b) contrast
 - c) graininess
 - d) sensitivity
- 34 Choose the incorrect option about x-ray tube using mammography.
- a) The target material is used molybdeum.
 - b) It is a rotating anode tube.
 - c) The Be window minimaizes beam hardening.
 - d) The tungsten target is used with film-screen mammography.

35 Choose the correct option about anti-scatter grid using mammography.

a)It is a pallarel grid.

b)It is a still grid.

c)It is a focusing grid.

d) An intermediate substance of a grid is used alminium.

36 Choose the correct option about heel effect.

a)The intensity is greater at anode side than at cathode side.

b)The quality f x-ray is harder at cathode side than at anode side.

c)X-ray intensity reduce toward the nipple side.

d)The heel effect of mammography is lower than that of general radiography.

37 choose the incorrect option of description about mammography equipment.

a)The eqipment can be adjusted in height and angular orientation.

b)The distance from the X-ray focus to the breast support platform is changeable.

c)It has a C shaped arm.

d)It has a compression paddle.

38 Choose the correct option in materials using output window of x-ray tube.

a)Al

b)W

c)Cu

d)Be

Choose the correct option about focal spot size used for conventional
39 mammography

a)0.15mm

b)0.3mm

c)0.45mm

d)3.0mm

Choose the correct option about highest compression power in equipment
40

a)80N

b)120N

c)150N

d)200N

Choose the incorrect option using a detector in digital mammography.
41

a)stimulable phosphor plate for CR

b)CsI scintillator

c)TFT

d)amorphous-Se

Choose the incorrect option about pixel pitch using flat pannel detector.
42

a)50 μ m

b)70 μ m

c)100 μ m

d)150 μ m

Choose the correct option about suitable voltage in the range.
43

a)15-25kV

b)25-35kV

c)35-45kV

d)45-55kV

16 Choose the correct option of tissue which has the lowest linear attenuation
44 coefficients.

a)glandular tissue

b)muscle

c)calcification

d)adipose

45 Choose the incorrect option about automatically selected conditions using AEC.

a)target

b)filter

c)tube voltage

d)tube current

46 Among the contrast of the Radiolgraphy, which of the following is NOT effect of the
46 film contrast factor?

a) Film fog

b) Developing conditions

c) Tube voltage

d) Screen characteristic

47 When the middle of the Tube- Object- film is not correct alignment, what is the result?

a) Blurring

- b) Magnification
- c) Size distortion
- d) Shape distortion

48 Which of the following is NOT correct characteristic of digital mammography?

- a) To be able to keep good contrast of image
- b) To be able to do some image processing after taking radiography.
- c) A characteristic of density is linear.
- d) Digital mammography has better spatial resolution than film mammography.

49 Which part of breast is the most mammary tissue exist?

- a) interior - upper part
- b) interior - lower part
- c) exterior - upper part
- d) exterior - lower part

50 Which of the following is NOT correct of lesion containing adiposity?

- a) galactocele
- b) hamartoma
- c) lipoma
- d) fibroma

51 Which of the following is NOT correct description of lesion?

- a) Bloody discharge from nipple in old people is suspected to malignancy.
- b) It is almost not bloody discharge in begin disease.

- c) Not able to distinguish fibroadenoma of mastopathy type at radiation image
- d) Noninfiltrating carcinoma following gangrene type calcification is low grade

52 Which of the following is NOT correct description about factor of increasing risk of getting breast cancer easily?

- a) Have no experience of having a baby
- b) One's mother get breast cancer.
- c) obesity
- d) having many experience of breast-feeding

53 Which of the following is NOT correct description about advantage of detect in early stage?

- a) improve survival rate
- b) unnecessary of postoperative therapy
- c) decrease lymph node metastasis
- d) decrease physical burden

54 Which of the following is NOT correct about adaptation of conservation therapy?

- a) The Size of mass is 1cm.
- b) Before preoperative therapy, mass gets smaller.
- c) There is axillary lymph node metastasis.
- d) not able to take radiation therapy after operation

55 Which of the following is the most standard preoperative therapy?

- a) hormonotherapy
- b) chemotherapy
- c) radiation therapy

d) molecular targeted therapy

56 Which is the most noteworthy characteristic about nipple discharge?

a) lactescent

b) watery

c) serous

d) bloody

57 Where is the sentinel lymph node in carcinoma of breast?

a) axillary lymph node

b) subclavicular lymph node

c) supraclavicular lymph node

d) parasternal lymph node

58 Which of the following is NOT appropriate description about an action for patient before taking mammography

a) Have patient do up her hair in a bun to avoid artifacts.

b) Cleaning mammography unit.

c) Politely explaining about the examination to relieve the anxiety.

d) In consideration of shyness, making the examination room completely dark.

59 Which of the following is the correct ratio of intramammary adipose tissue in Dense Breast?

a) 70~90%

b) 40~50%

c) 30~40%

d) 20~10%

60 Which of the following is NOT correct evaluation items of masses by palpation?

- a) size
- b) shape
- c) border
- d) flare

61 Which of the following is correct relative hormone and function?

- a) Estrogen – is secreted in the anterior pituitary gland during pregnancy. It makes breast growth and galactoria acceleration.
- b) Oxytocin – supply for amino acid, fatty acid, grape sugar and calcium to mother's milk
- c) Prolactin – develop mammary duct length and proliferate linear organization
- d) Progesterone – increase mammary duct and epithelium of the lobule, and the acinar grow acceleration become pregnancy

62 What is the Montgomery Gland function?

- a) Evacuator function
- b) Stimulate function
- c) Stabilization function
- d) Lubrication function

63 Which of following is correct of lymph node around breast?

- a) axillary lymph node
- b) subclavicular lymph node
- c) supraclavicular lymph node
- d) mesenteric lymph node

64 Which of the following is correct for the Galactocele?

- a) Traumatic breast disease
- b) Benign cyst contain of the lactation
- c) Calcification of the shell-shaped
- d) Mammary cystic hyperplasia contain of the lactation

65 What is NOT the histological name of the mammary duct?

- a) Myoepithelial cells
- b) Epithelial cells
- c) Basement membrane
- d) Cutaneous lymphathic plexus

66 Which of the following is NOT describe of the DCIS(Ductal Carcinoma In Situ)?

- a) Treatment is cure, and prognosis is better
- b) DCIS with micro calcification
- c) Palpable mass occurred 20~30 years
- d) Limit in the only ductal, and often occurred TDLU

67 Which of the following is NOT correct for the purpose of the Diagnostic Mammography?

- a) When abnormal site find in the screening test
- b) After Radiation Therapy exam to mastectomy patient
- c) Has a blood discharge symptom of the other breast
- d) Request of the micro-calcification from other hospital

68 Which of the following is correct description of the BI-RADS?

- a) Organization of terms and report system
- b) Differentiation of the reading of breast image and patient care
- c) For communication of reading in a hospital
- d) The first generation in 1992 included Mammography, Breast Ultrasound and Breast MRI

69 Which of the following is appropriate target of stereo guided tissue biopsy?

- a) inflammatory diseases
- b) local breast microcalcification
- c) small tumor lesion
- d) diffuse diseases

70 Which of the following is NOT correct about the BSE (Breast Self Exam)?

- a) After finishing menstruation every month
- b) Compare to change of the nipples shape
- c) Using 2nd, 3rd and 4th fingers touchable in clockwise
- d) Every month check after ovariectomy or becoming menopause naturally

71 Which of the following is NOT correct description?

- a) You can distinguish between fibroadenoma and phyllodes tumor easily.
- b) Mucinous carcinoma is terminally differentiated invasive carcinoma.
- c) a person with inflammatory breast cancer get reditchy skin.
- d) Fat necrosis changes to oil cyst.

72 Which of the following is NOT correct description?

- a) Cicatrices radials has central density.

- b) There is not cytoclasis in noninfiltrating calcinoma.
- c) You need to distinguish between cytoclasis and malignancy.
- d) A person with rheumatoid arthritis and collagen disease get axillary lymphadenopathy.

73 Which of the following is NOT correct description?

- a) Some of benign tumor have spicula.
- b) In phyllodes tumor, rapid enlargement suggestion a low-grade cancer.
- c) In noninfiltrating calcinoma, what cause from lobules suggestion a high-grade cancer.
- d) Tuth noninfiltrating calcinoma has capability of metastasizing.

74 Which of the following is NOT correct description?

- a) Some patient with breast cancer have dimpling.
- b) Stage-0 means T1N0M0.
- c) T3 means that lump is over 5cm.
- d) M1 means that there is distant lymph node metastasis.

75 Which of the following is NOT correct description?

- a) The purpose of aspiration biopsy cytology is examination to diagnosis benign or not, when it is detected with breast ultrasound examination.
- b) For impalpable lesion suspected of malignancy detected by mammography, it need to take stereo guided biopsy.
- c) It is useful to take non-contrast breast MRI examination.
- d) The main purpose of breast CT is diagnosis of extent of lesion.

76 Which of the following is NOT correct description?

- a) Possibilities of detect sentinel lymph node increase with using coloring gent and isotope examination at the same time.
- b) A dimpling appears after surgery and trauma.

- c) If there is sentinel lymph node metastasis, it is operated by typical mastectomy.
- d) If cancer and inflammation infiltrate to subcutaneous and cooper's ligament, there is the skin excavation.

77 Which of the following is NOT correct of masses following spicula?

- a) infiltrating duct carcinoma
- b) cyst
- c) abscess
- d) sclerotic lesion

78 Which of the following is correct description about constitution of lesion of well defined?

- a) colloid carcinoma
- b) phyllodes tumor
- c) fibroadenoma
- d) intraductal papilloma

79 Which of the following is correct description line up in malignancy order about distribution of calcification?

- a) diffuse/regional-grouped-linear/segmental
- b) linear/segmental-grouped-diffuse/regional
- c) grouped-diffuse/regional-linear/segmental
- d) diffuse/regional-linear/segmental-grouped

80 Which of the following is NOT correct description of clear benign calcification?

- a) round calcifications
- b) lucent-centered calcifications
- c) milk of calcium calcifications

d) branching calcifications

81 Which of the following is NOT correct about characteristic image of breast cancer?

- a) including adiposity
- b) follow spicula
- c) follow traction nipple
- d) high densit

82 Which of the following is most appropriate shape of malignancy suspected masses?

- a) round
- b) oval
- c) lobular
- d) irregular

83 Which of the following is NOT correct description about interpretation?

- a) When there are some findings, you need to evaluate them in order of malignancy.
- b) About calcification, you evaluate morphology and distributions.
- c) You don't need to consider calcification with masses.
- d) It is preferable a comparative interpretation.

84 Which of the following is NOT correct description?

- a) In FAD (focal asymmetric density), it reveals true lesion and significant architectural distortion by extra examination,
- b) It is relatively difficult to detect lesion in ununiformity and high density mammary gland.
- c) You need to comment of examination observations for swelling lymph node that is 't permuting for adipose.
- d) Architectural distortion is observation of benign.

85 Which of the following is NOT correct description?

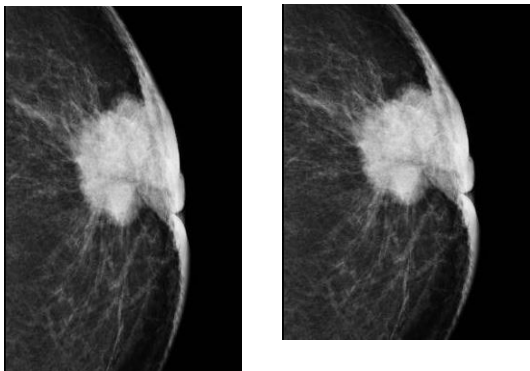
- a) A mention of structure mammary gland indicates the extent of danger that lesion hides normality mammary gland.
- b) In fatty, scattered fibroglandular densities, ununiformity and high density and high density, the easiest to observe lesion is ununiformity and high density.
- c) A difficult to evaluation means that a part of lesion(margin) is hidden by adjacent or overlap mammary gland
- d) A structure of mammary means a dependability of interpretation.

86 71. Which of the following is NOT correct description?

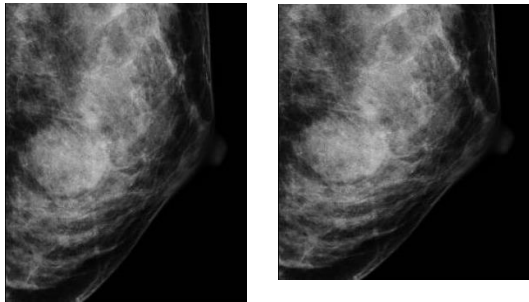
- a) Adipose tissue is caught in a breast cancer.
- b) A margin is not considered in evaluation of shape
- c) The principal of breast cancer doesn't include adipose.
- d) In order of the possibility of malignancy, unfairness, polygon, lobulation shape and round shape are ranked.

87 Which of following image is correct of infiltrating cancer?

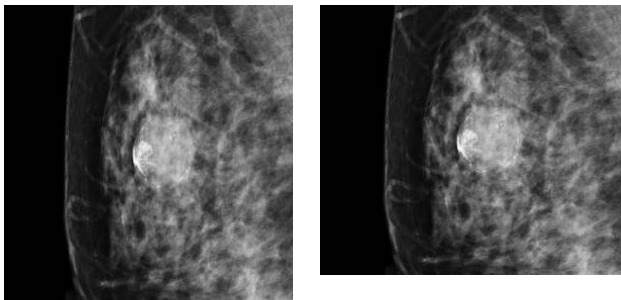
a)



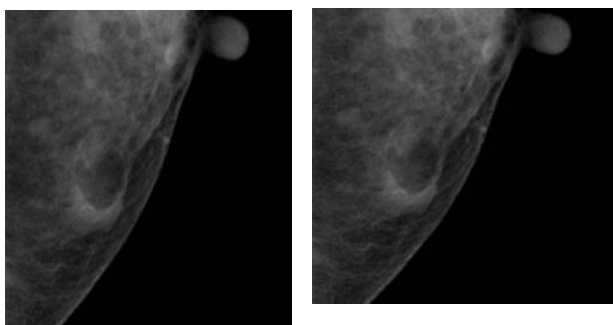
b)



c)

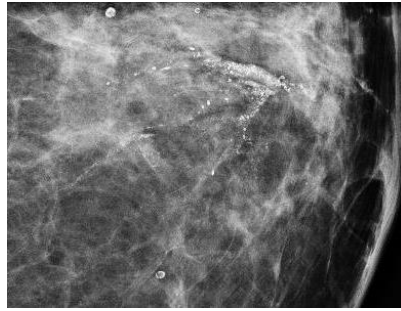
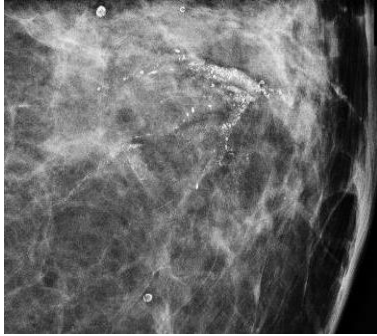


d)

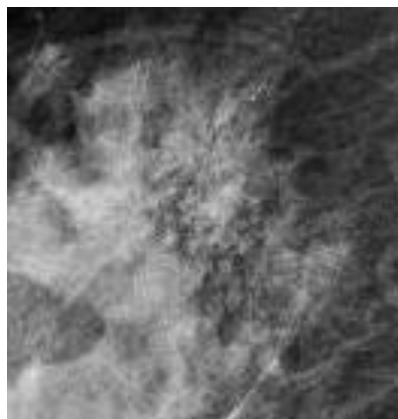
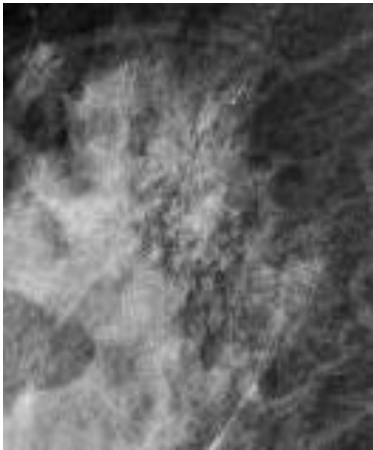


Which of following image is a calcification that don't have to differentiating
88 between malignant and benign disease?

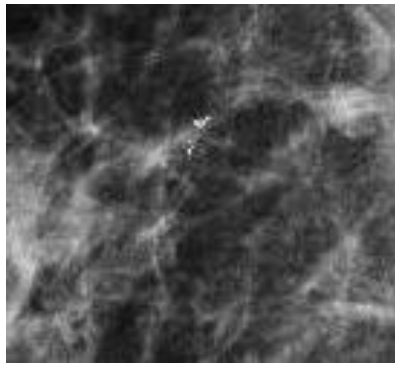
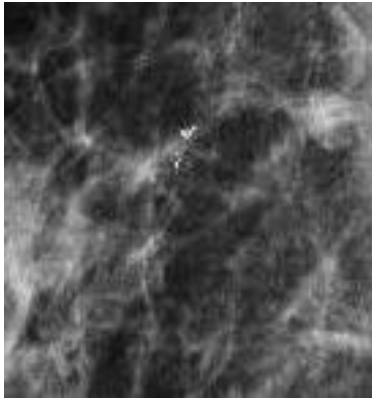
a)



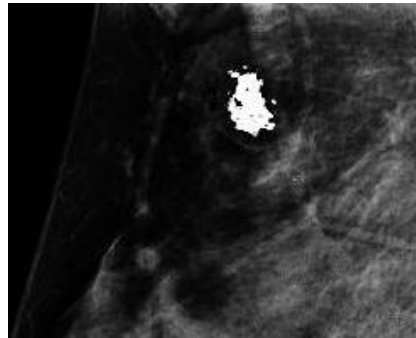
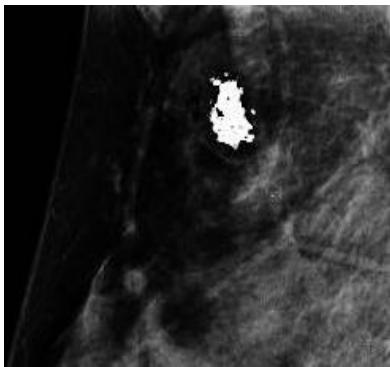
b)



c)

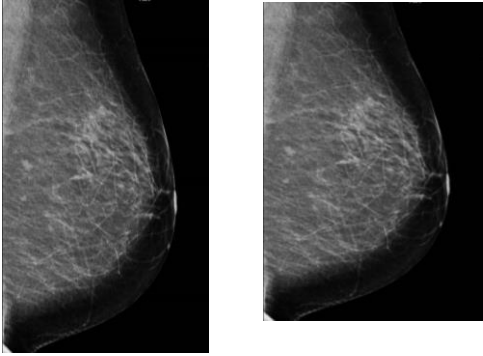


d)

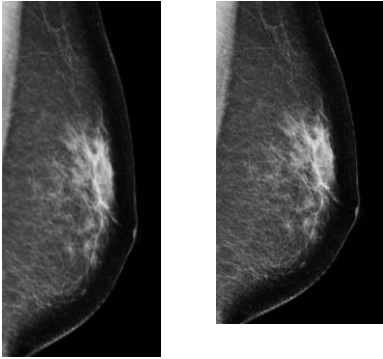


Which of following image is the most appropriate for a mammography of fatty-
89 breast?

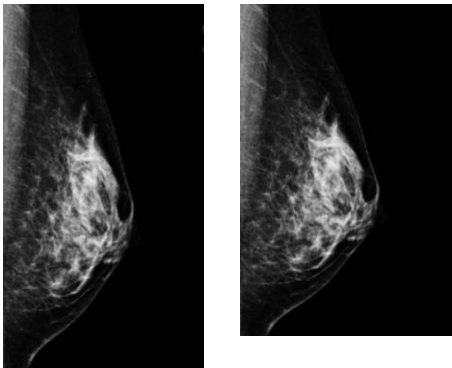
a)



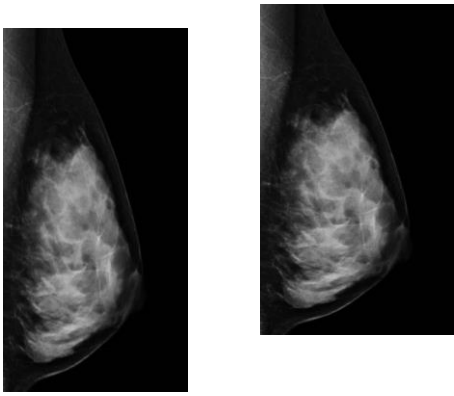
b)



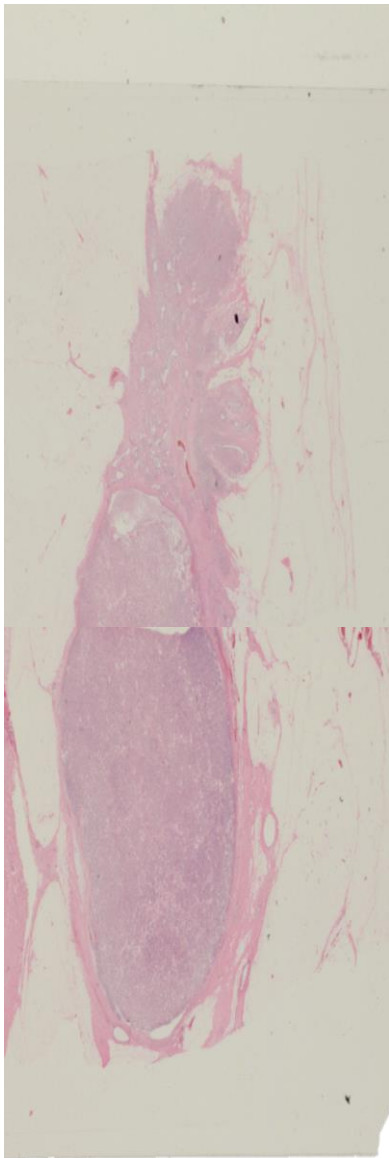
c)



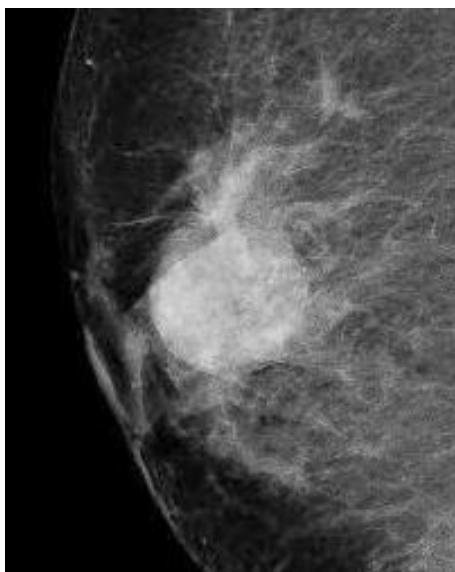
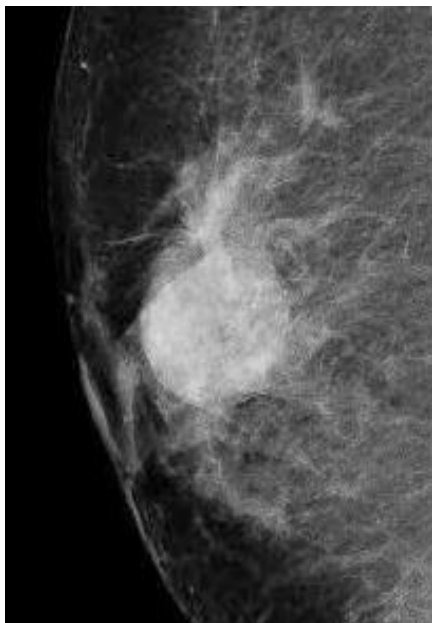
d)



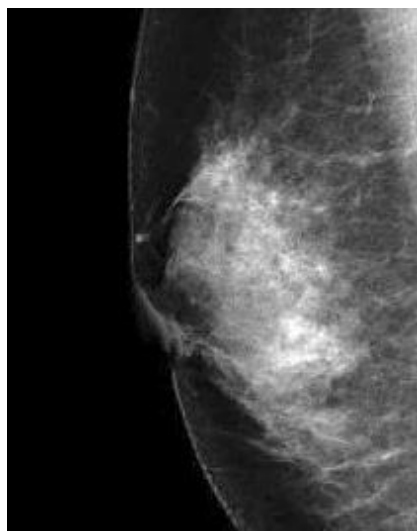
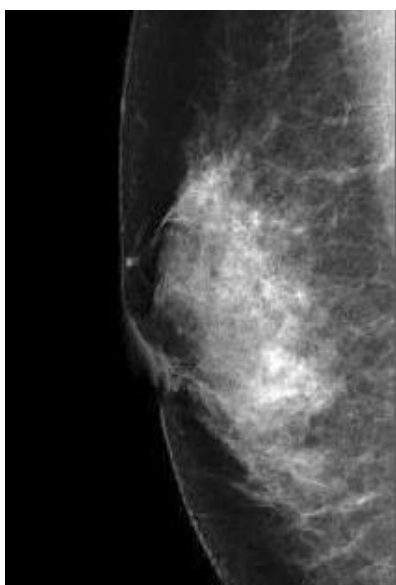
90 Which of mammography image is that presents the following pathological image?

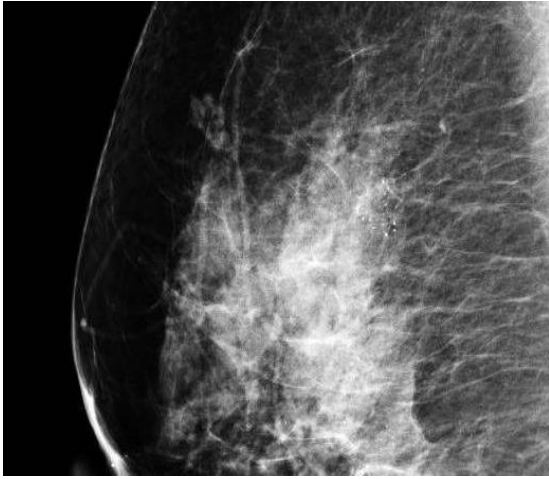


a)

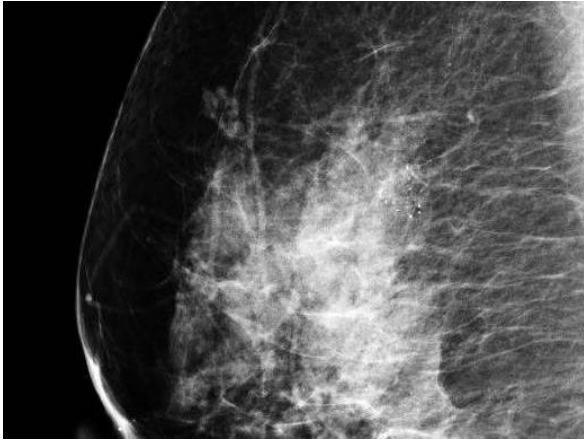


b)

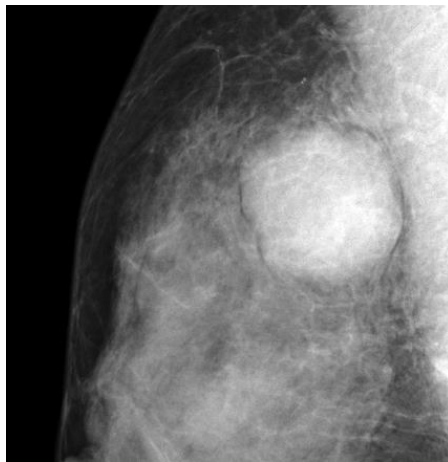
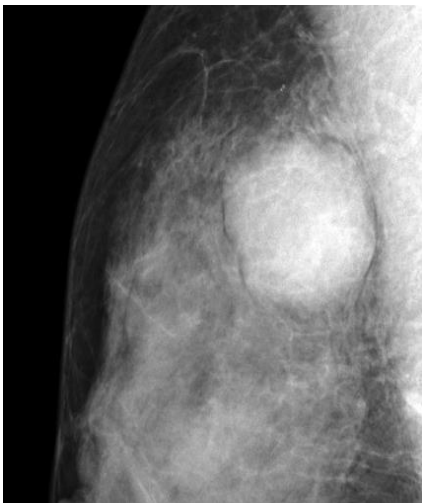




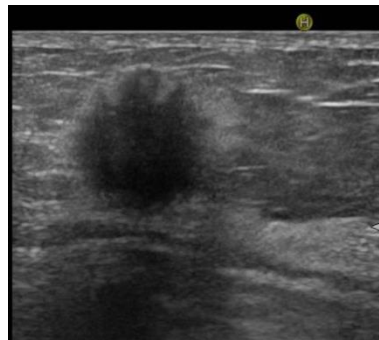
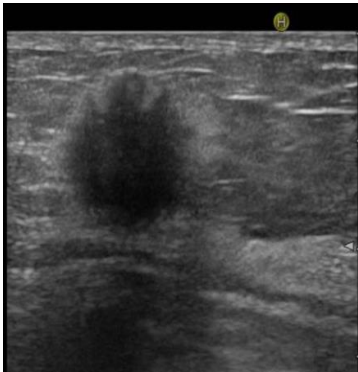c)



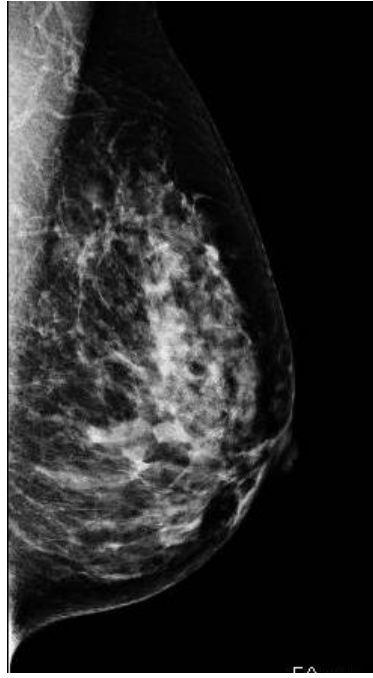
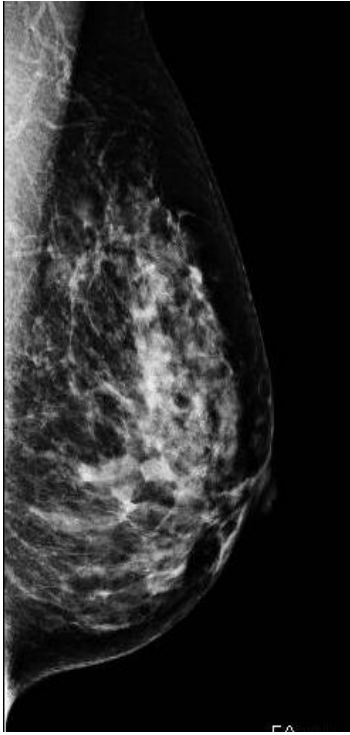
d)



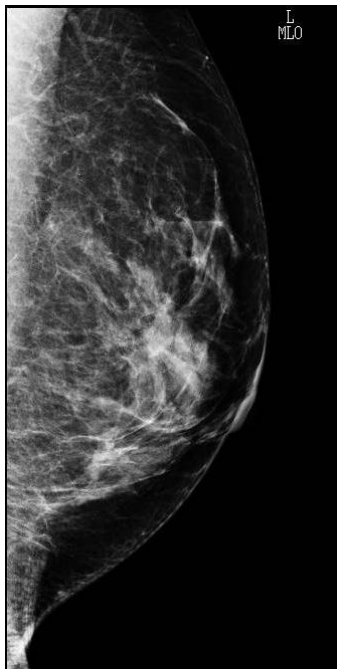
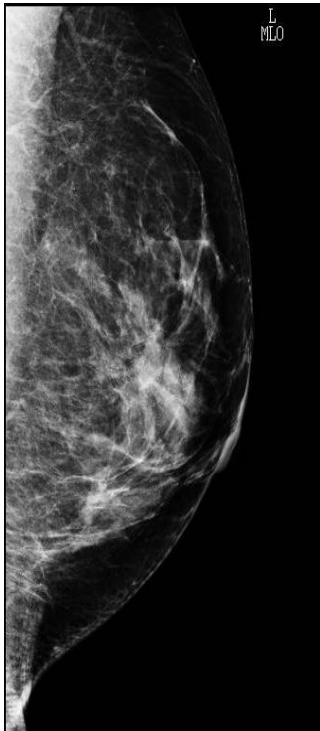91 Which of mammography image is that presents the following ultrasound image?



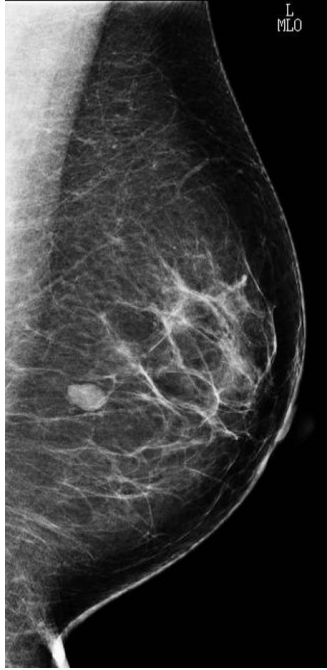
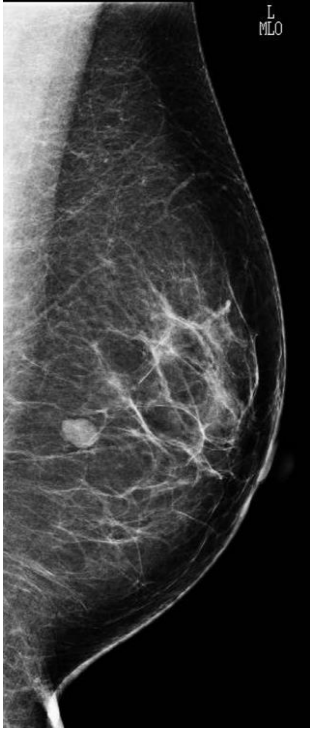
a)



b)



c)



d)

