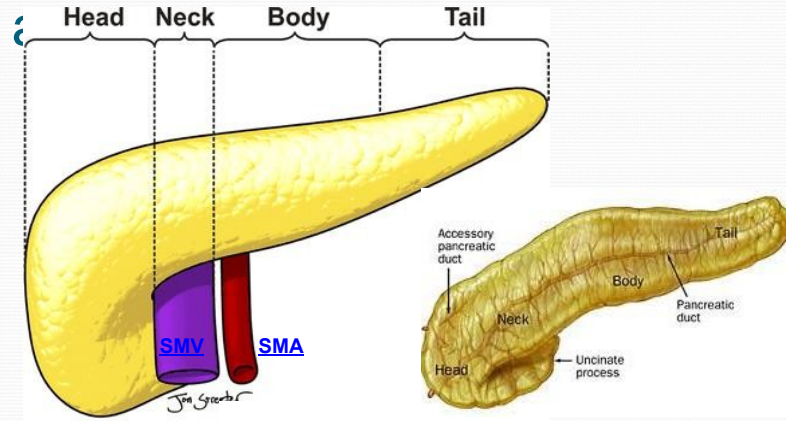


胰脾腎主動脈超音波掃描簡介

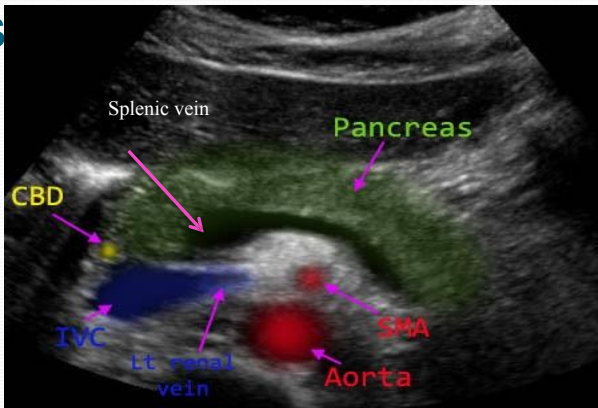
高雄榮總放射線部 黃文娟 放射師
2019.8.18

Pancre



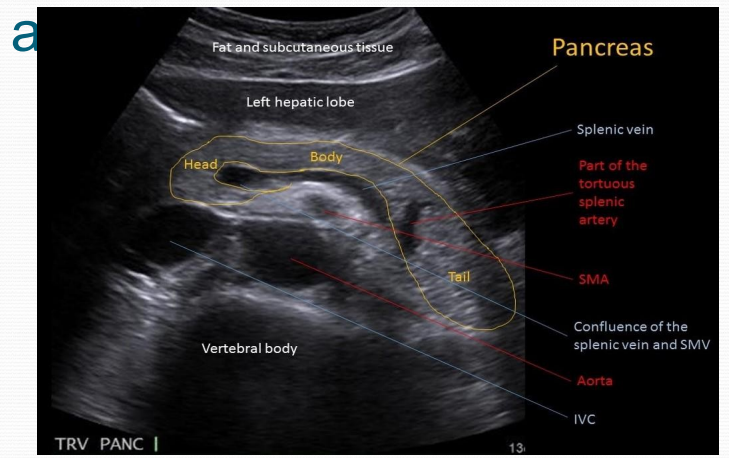
<http://radiographics.rsna.org/content/26/3/715/F7.expansion.html>

Pancre as



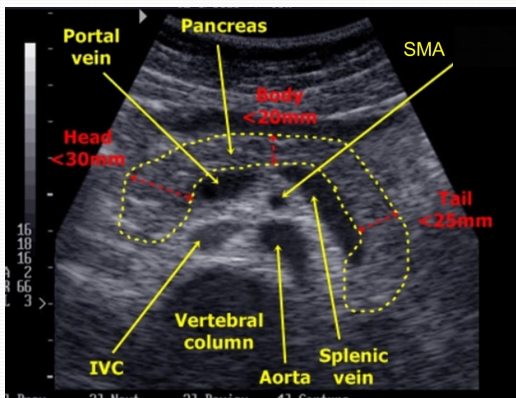
<https://www.ultrasoundpedia.com/uploads/530031/files/pancreas/pancreas-normal-ht.jpg>

Pancre



<https://radiopaedia.org/cases/37581> ID: 37581

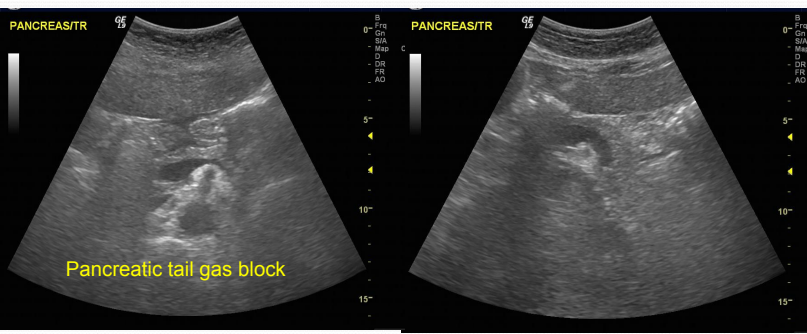
Pancre as



Pancre

- as 位於後腹腔易受胃內氣體及腸氣的影響
- 請病患深吸氣後閉氣(肚子鼓起來)
 - 腸氣多或肥胖的病患可稍加壓迫
 - 較瘦病患輕壓並輕輕吸氣即可
 - pancreatic head請病患向右側躺
 - pancreatic tail請病患向左側躺

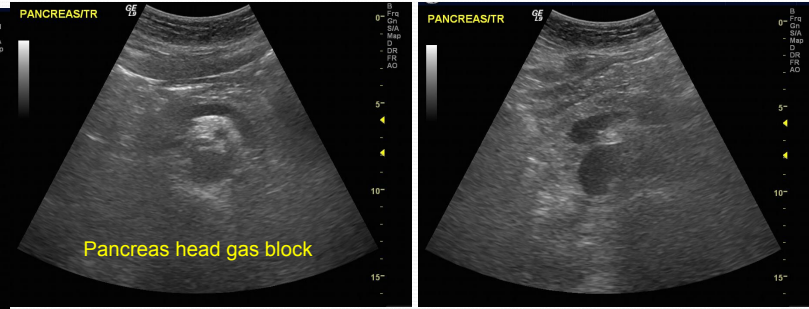
Pancrease-腸氣-掃描技巧-改變姿勢



平躺

向左側躺

Pancrease-腸氣-掃描技巧-改變姿勢



平躺

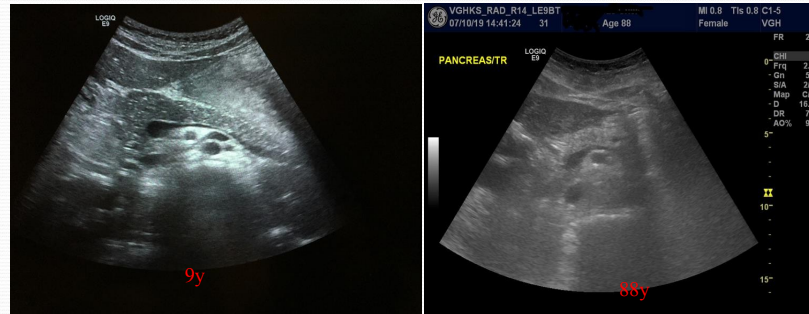
向右側躺

Pancre

- 請病患坐起來
- 喝水(讓胃當介質)

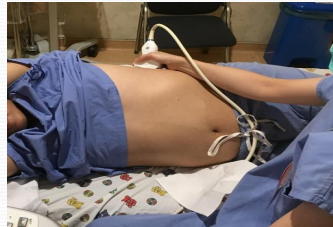Pancre

- 兒童或年輕人,體積大且回音比Liver低
- 成人正常回音比Liver略高
- 老年人體積小,回音比Liver高

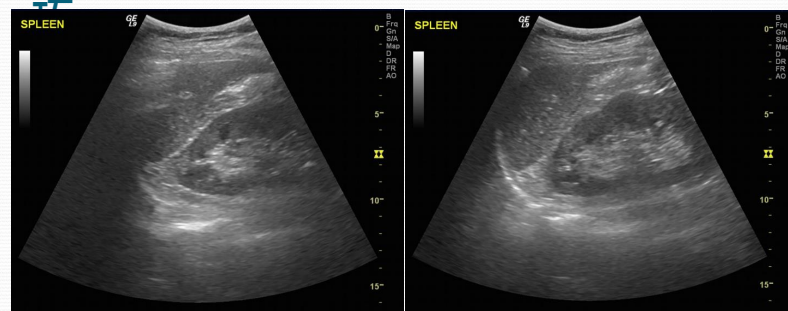


Splee

- 在splenic flexure和胃的後方
- 右側躺或平躺姿勢
- 回音:Spleen≤Liver
- 可以當作左腎和胰臟尾部的聲波介質
- 正常成人<12cm
- Splenomegaly>12cm



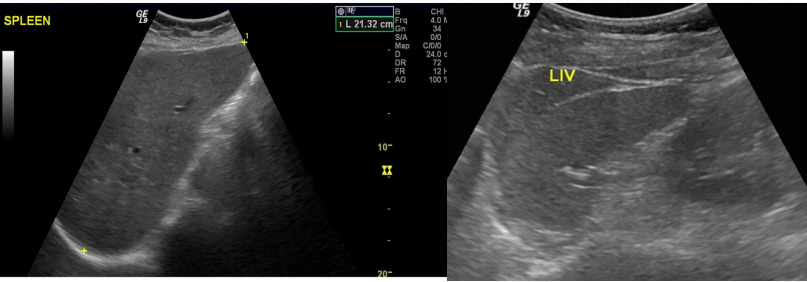
Spleen-掃描技



深吸氣

輕輕吸氣

Spleen

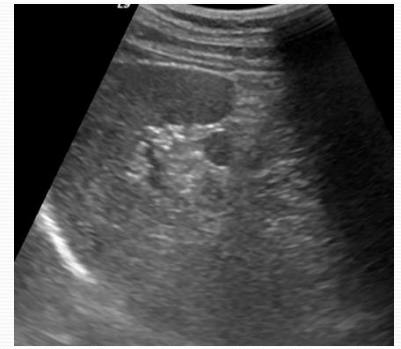


Splénomegaly

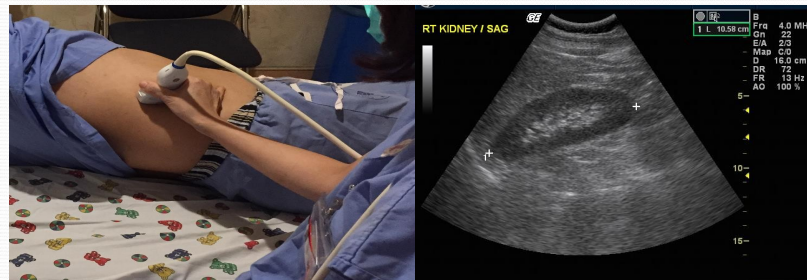
Lingulate lobe of liver(舌狀肝)

accessory spleen(副脾)

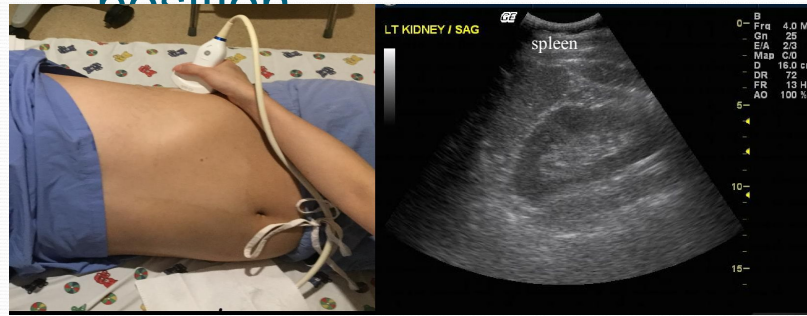
- 通常出現在hilum 附近
- 回音與Spleen相同
- Oval or Round
- 一個或數個(少見)
- Spleen切除後,也有可能
有腫大的情形



RT kidney scanning position

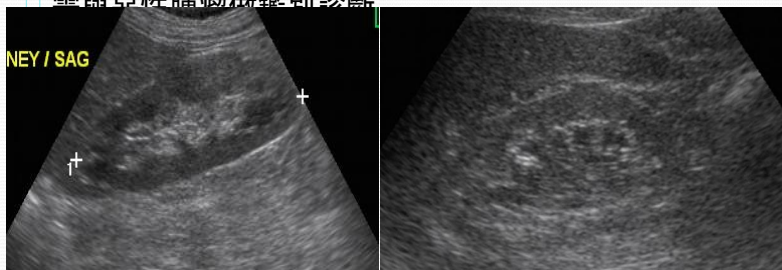


LT kidney scanning position



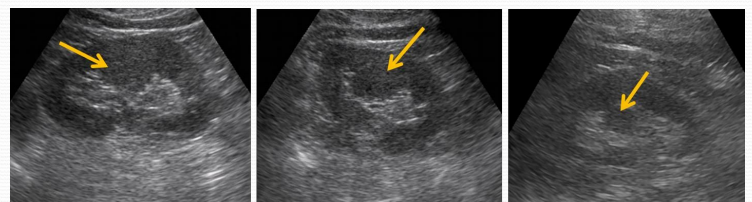
Renal sinus lipomatosis

- 需與亞性腫瘤做鑑別診斷

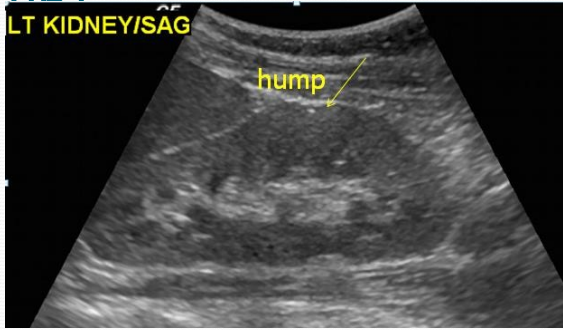


Column of

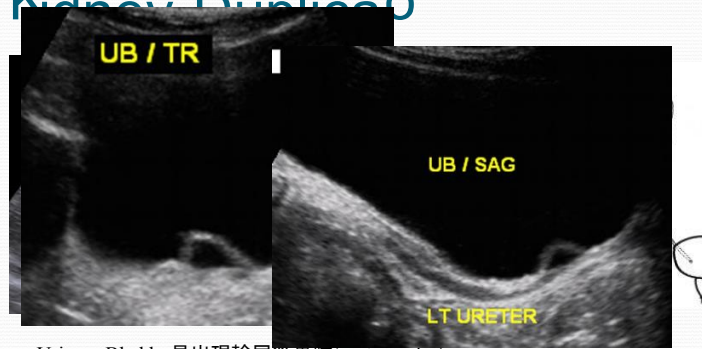
- 腎皮質延伸到腎竇裡去的部分
- 發生在胎兒腎臟小葉之間
- 需與惡性腫瘤做鑑別診斷(On Color Doppler)



Renal hump(dromedary hump)



Kidney Duplication

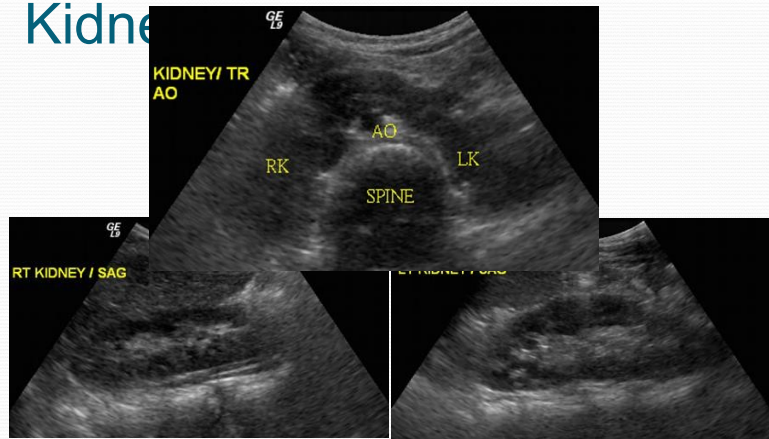


- Urinary Bladder易出現輸尿管囊腫(ureteroceles)
- hydronephrosis, most often the upper pole system

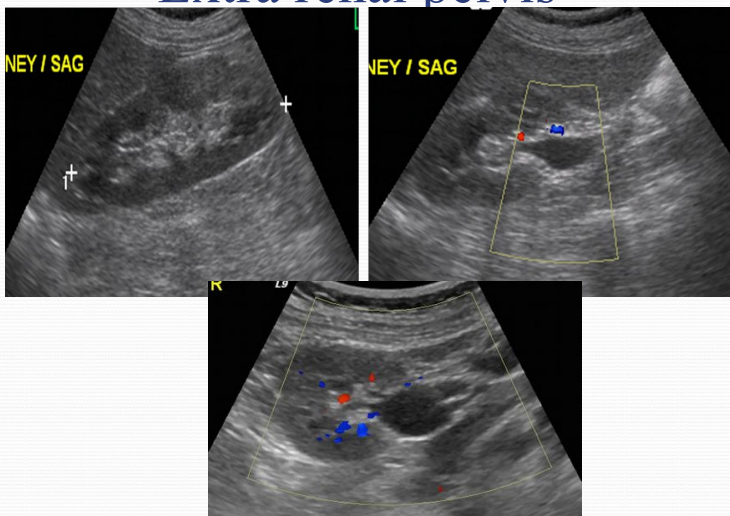
Horseshoe Kidney

- renal stone
- ureteropelvic junction(UPJ) obstruction

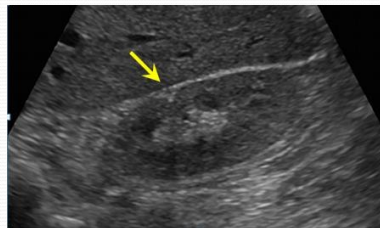
Horseshoe Kidney



Extra renal pelvis

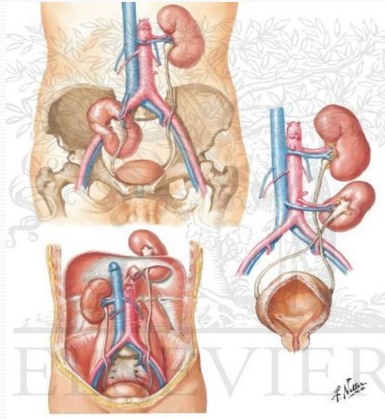
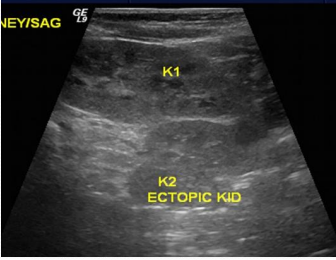


Junctional parenchymal



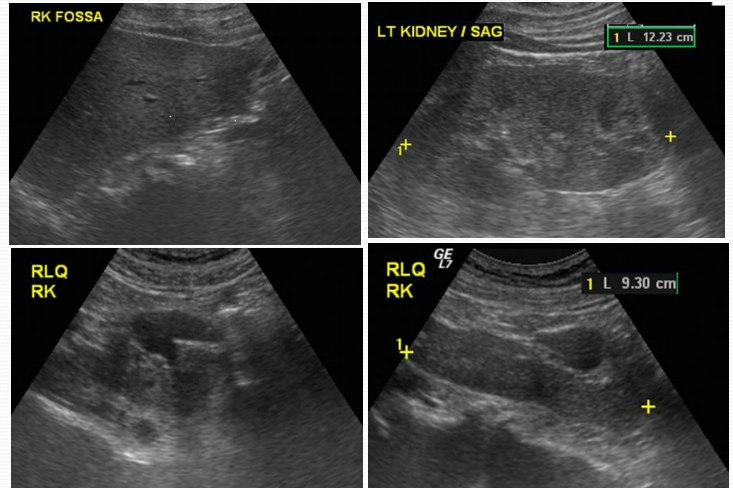
- 胚胎時期分葉融合不完全造成
- 常見upper pole of right kidney

Ectopia kidney

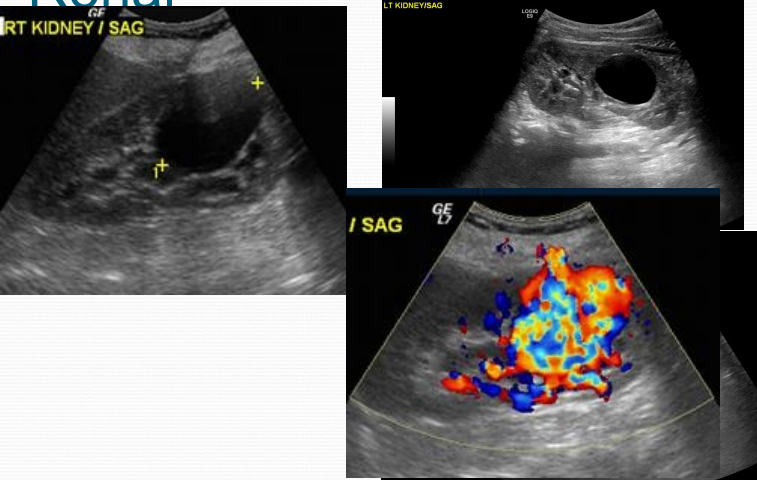


<https://www.netrimages.com/ectopia-of-the-kidney-amlabeled-embryology-frank-h-natter-1721.html>

Ectopia

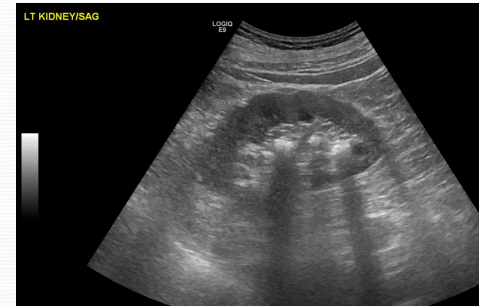


Renal



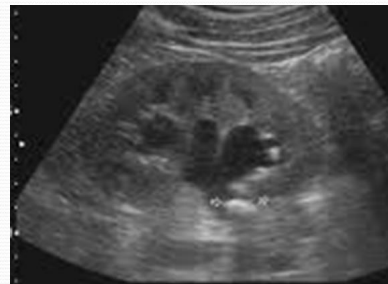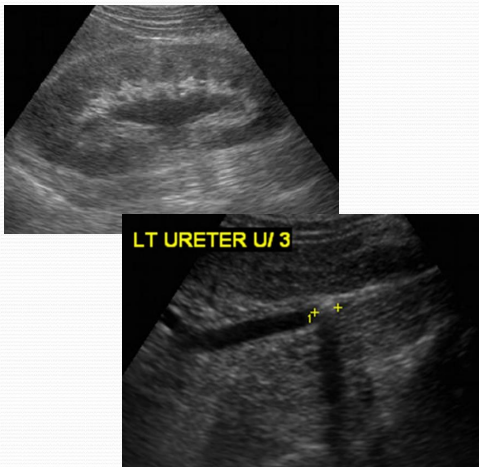
Renal stone

- Hyperecho
- Acoustic shadowing (後方陰影)

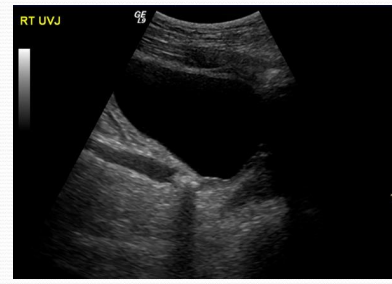


Hydronephrosis

- is Stone
- Tumor
 - Stenosis
 - Infection
 - 壓迫
 - 過度漲尿
 - 手術
 - 外傷

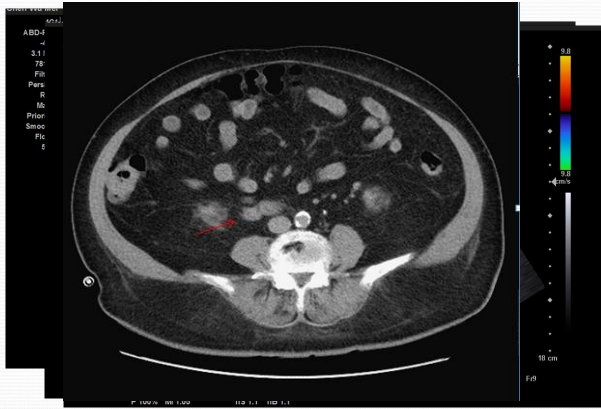


Ureteropelvic Junction (UPJ) stone

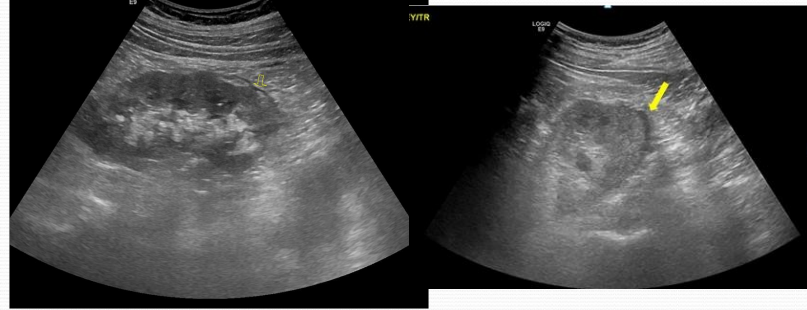

Ureterovesical Junction (UVJ) stone

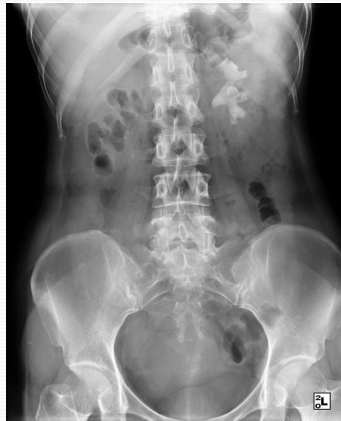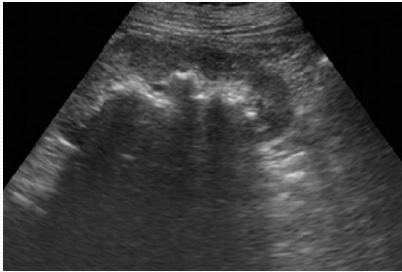
Hydronephrosis



Urinoma 尿液囊腫



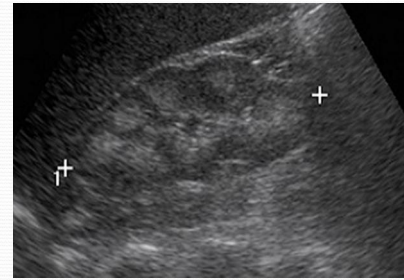
Staghorn calculi (鹿角石)



Nephrocalcinosis 腎石灰沉著

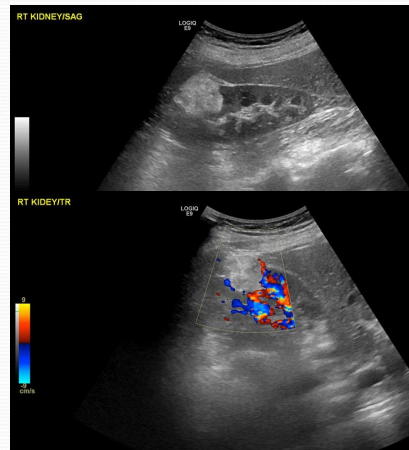
系統代謝疾病或腎小管異常引起的鈣質沉積

- 好犯在髓質錐體
- 常見疾病: 痛風腎病變、遠端腎小管酸血症、原发性醛酮過多症....等
- 二側腎錐體回音變高, 可伴隨有或無陰影(微小鈣聚積)

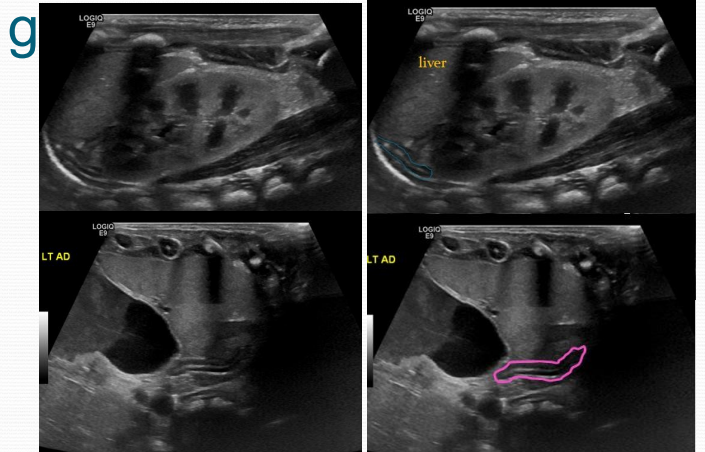


Angiomyolipoma 血管肌肉脂肪瘤

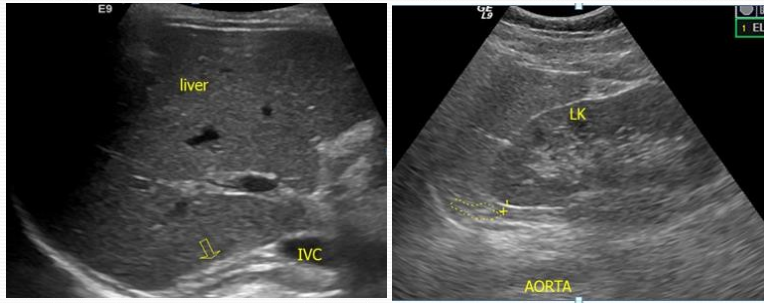
- 含脂肪肌肉和血管之良性腫瘤
- 又稱Hamartoma (過誤瘤)
- 好發中年女性
- hyper echo .
- Color flow : 無 或弱
- 單顆(80%在右邊)
- 無臨床症狀



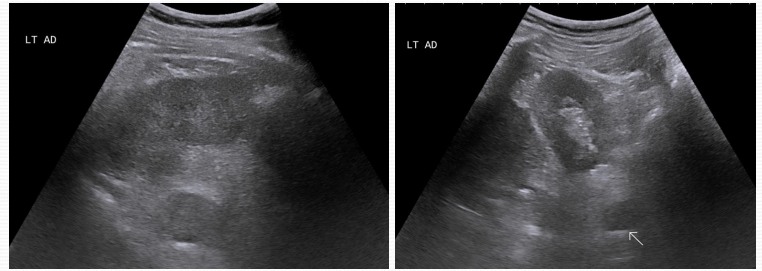
Adrenal



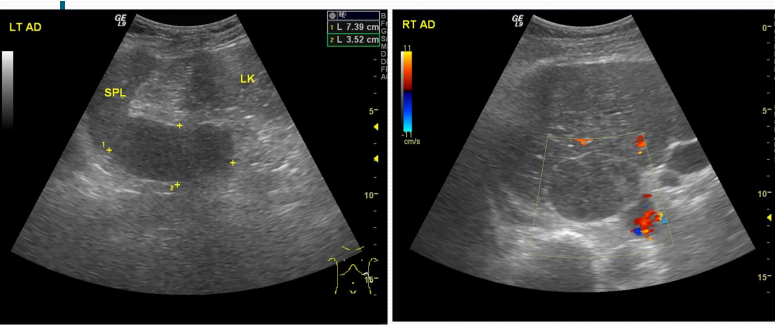
Adrenal glands



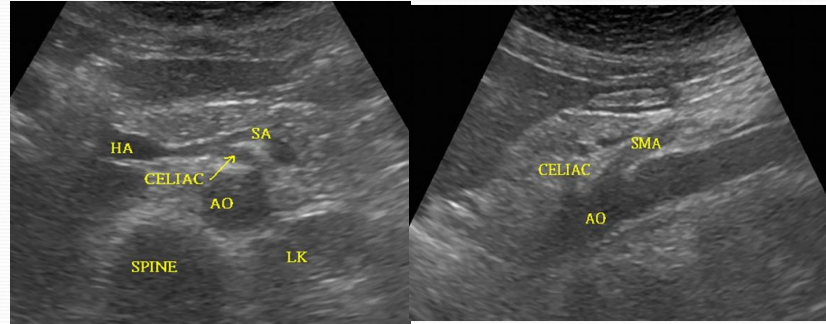
Adrenal Adenoma



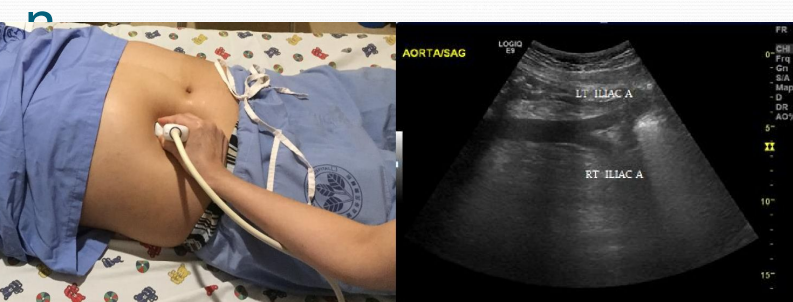
Adren



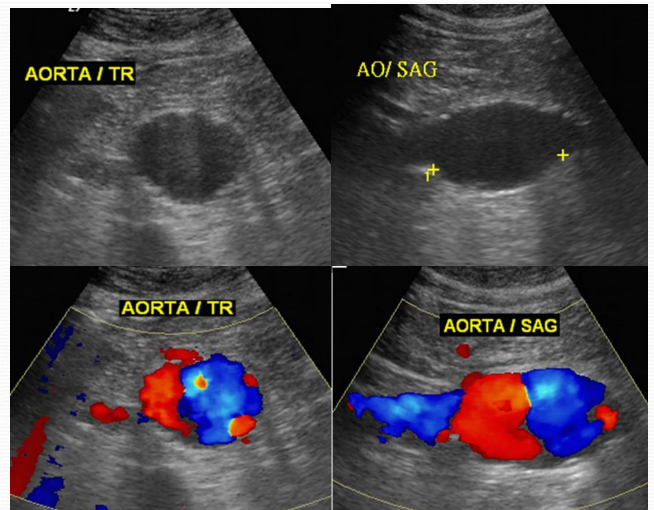
aort



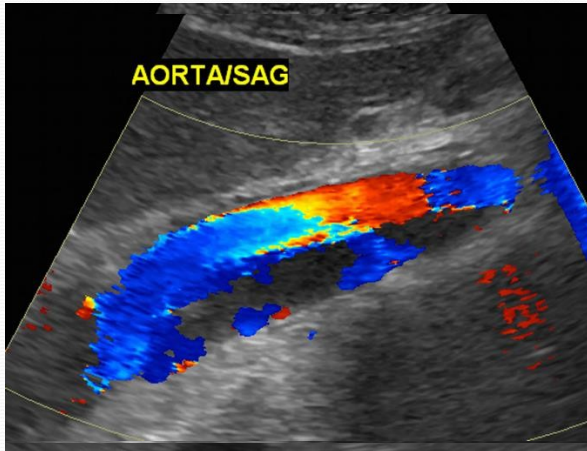
Aorta-bifurcatio



主動脈瘤 Aorta Aneurysm



主動脈瘤Aorta



參考資料

- <https://www.ultrasoundpaedia.com/uploads/53003/ufiles/pancreas/pancreas-normal-hl.jpg>
- <https://radiopaedia.org/cases/37581>">rID: 37581
- <https://radiopaedia.org/cases/37581>">rID: 37581
- <http://www.startradiology.com/uploads/images/english-class-ultrasound-abdomen-general-fig11-normal-kidney-met.jpg>
- <http://radiographics.rsna.org/content/26/3/715/F7.expansion.html>
- <https://www.chop.edu/conditions-diseases/horseshoe-kidney>
- <http://www.urology-textbook.com/duplex-kidney.html>
- <https://www.ncbi.nlm.nih.gov/pubmed/3880914>
- <https://www.netterimages.com/ectopia-of-the-kidney-unlabeled-embryology-frank-h-netter-1721.html>
- <https://kb.commonhealth.com.tw/library/110.html><http://www2.cmu.edu.tw/~c-mcmd/ctanatomy/clinical/angiomyolipoma.html>
- <https://www.xuehu.us/2018/06/21/%E8%82%BE%E8%84%8F%E5%AE%9E%8%B4%A8%E5%86%85%E7%BA%BF%E6%A0%B7%E9%AB%98%E5%9B%9E%E5%A3%B0%EF%BC%8C%E4%BC%9A%E6%98%AF%E4%BB%80%E4%B9%88%E5%91%A2%EF%BC%9F-jpd/zh-tw>
- <http://images.yourdictionary.com/adrenal-gland>
- 腹部超音波 新手上路快易通 / 合記出版社
- 超音波診斷學手冊 / 合記出版社
- 醫學影像診斷學 / 合記出版社

感謝聆聽!!